

Possibilities of Endovideolaparoscopic Methods of Treatment of Abdominal Adhesive Disease in Children.

Received: 22 October 2022, **Revised:** 16 November 2022, **Accepted:** 24 December 2022

Berdiev Ergash Abdullayevich¹, Salimov Shavkat Teshayevich², Abdusamatov Bobir Zakirovich³, Atakov Sarvar Sultanbaivich⁴, Kasimov Ulugbek Kurkmasovich⁵, Ollanazarov Jasurbek Otajanovich⁶.

¹Candidate of Medical Sciences, docent of the Department of General and Pediatric Surgery №1 of the Tashkent Medical Academy, Tashkent Uzbekistan

²Doctor of Medical Sciences, Professor of the Department of General and Pediatric Surgery №1 of the Tashkent Medical Academy

³Doctor of Medical Sciences, docent of the Department of General and Pediatric Surgery №1 of the Tashkent Medical Academy. Director Republican Children's Scientific and Practical Center for Minimally Invasive and Endoscopic Surgery.

⁴Candidate of Medical Sciences, docent of the Department of General and Pediatric Surgery №1 of the Tashkent Medical Academy

⁵Candidate of Medical Sciences, Docent of the Department of General Surgery №1 of the Tashkent Medical Academy

⁶Assistant of the Department of General and Department of General and Pediatric Surgery №1 of the Tashkent Medical Academy.

Key Words:

adhesive disease, fibrinolysis, laparoscopy, children, prevention.

Abstract:

The use of endovideolaparoscopic adhesiolysis in combination with FLA in the article is the most pathogenetic and less traumatic method, it plays a major role in the early prevention of the adhesive process in the abdominal cavity. Excellent coverage and accurate visualization of organs and their changes in the abdominal cavity allows you to determine the type of adhesive process and choose the necessary treatment tactics.

1. The Relevance of the Study.

Despite modern progress in medical science, the problem of postoperative abdominal adhesions (PAP) and peritoneal adhesive disease (PAD) remains one of the urgent problems of general surgery. The main reason of the development of adhesions after surgery is damaging the peritoneal mesothelium. The number of patients suffering from PAD increase continuously in proportion to the number of surgical interventions and adhesive complications occupy one of the first places in the postoperative mortality (Timofeev M.E., Shapovalyants S.G., Larichev S.E 2011). Many issues of the pathogenesis of adhesive disease of the peritoneum, its prognosis, prevention and treatment tactics remain controversial (Kozlov O.A., Troyan V.V., 2007; Baranov G.A., Karbovsky M.Yu., 2012).

According to the International Adhesion Society (International Adhesion Society, 2001), about 1% of previously operated patients are treated annually in

surgical departments for adhesive disease, 50-75% of this category of patients develop intestinal obstruction with high mortality. Conservative treatment of adhesive disease is ineffective, and after surgical interventions, relapses are observed from 32 to 71%. Reliable means of preventing PAP, as indicated by R. D. Magalashvili (1991), MP Diamond, DM El-Mowafi (1998), DM Wiseman (1999), A. A. Vorobyov, A. G. Beburashvili (2001 - 2009), I. A. Chekmazov (2002) and many other authors are missing.

Despite a significant number of publications, which reflects data of several hundreds of experimental and clinical studies on adhesive disease (AD), this problem is far from being solved (Lazarenko V.A., Lipatov V.A., 2012, Di Saverio S, Coccolini F, Galati M e t al .). The etiological factors for developing of adhesions in the abdominal cavity are extremely diverse and many pathogenetic mechanisms

Journal of Coastal Life Medicine

have not yet been elucidated fully. (Salimov.Sh.T. Berdiev E.A, 2009; Ambiru S., Furuyama N., 2008).

Aim of the study: to improve the results of the treatment of adhesive disease in children by early prevention and optimization of the tactics of surgical adhesiolysis.

2. Materials and Methods:

Between 2010 and 2022 in RSPCMIESCh laparoscopic adhesiolysis was performed in 111 patients aged from 3 to 17 years. Of these, 89 are initially hospitalized patients and 22 are readmitted patients from the control group with relapse of AAIO, 11 of them were previously discharged after conservative relief of symptoms of AD and 7 patients were previously operated on by traditional laparotomy for AAIO (of which 4 patients FLS was used, in 7 FLS was not used).

All patients of the main group were previously operated on, in 111 (75,7%) cases an appendectomy was performed initially, appendicular peritonitis was in 15(13.6 %) children, 2 (1.8%) children were operated on for a closed injury of the abdominal organs. cavity and laparotomy was performed after trauma of the abdominal organs in 3 (2.7%), laparoscopic hernioplasty was performed in 2(1.8%).

During the period of preoperative preparation, in order to resolve the obstruction clinic, the patients underwent planned standard intensive conservative therapy. However, it was not possible to restore the passage and intestinal motility in any of these patients. Due to the lack of effect from conservative therapy, it was decided to perform a laparoscopy, which had two goals; the first is diagnostic , i.e. to conduct an audit of the abdominal organs, to establish the places of obstruction; the second is to perform video-laparoscopic adhesiolysis, separate visceroparietal, omental, inter-intestinal adhesions and restore the intestinal passage.

In the preoperative period, these children underwent the necessary clinical and laboratory tests; coagulogram before surgery, then during surgery and in the dynamics of the postoperative period, within 7 days. Before surgery, in all patients of the main group, blood coagulation parameters were within the normal range, up to 246.1 ± 2.4 sec on average, blood clot retraction was $39.0 \pm 0.5\%$, plasma tolerance to

heparin ($10.4 \pm 0, 3$ min) and fibrinogen level (3.84 ± 0.6 g/l) were within the upper limit of normal.

3. Results of Laparoscopic Adhesiolysis.

After insufflation of nitrous oxide, FLS was initially injected into the abdominal cavity, then, during revision, the presence of obstructing factors (adhesions, volvulus) was clarified.

Separation of viscerovisceral adhesions consisted of tensioning the adhesion, separating it with the help of manipulators, a dissector, and cutting it in a blunt and sharp way, followed by mono- or bipolar coagulation. Loose inter-loop adhesions were easily destroyed in a blunt way. In the presence of rough inter-intestinal adhesions, gentle, precise dissection of intestinal loops and adhesions was performed.

In 67 (60,3%) patients out of 111, the separation of adhesions between the postoperative wound and the omentum was not difficult. In the remaining 11 (9.9%), during the separation of interintestinal adhesions, the following were found: planar adhesions in - 1 patient, in - 5 a picture of a pronounced inflammatory process in the intestinal wall with microcirculatory disturbance was visualized, in - 19 (17,1%) children a diffuse adhesive process was found, occupying 2/3 of the abdominal cavity, and a conglomerate of intestinal loops with multiple areas of compression of the intestinal lumen (3-4 degree of adhesion prevalence) was visualized. Due to technical difficulties, the massiveness of the multiple adhesive process in - 12 (10,8%) cases, it was decided to perform a conversion - laparotomy, revision, dissection of adhesions deforming the intestinal lumen, separation of intestinal loops, drainage of the abdominal cavity.

In the ICU on the first day of the postoperative period, these patients were gradually injected with FLS into the abdominal cavity (in order to activate the processes of proteolysis and fibrinolysis, resorption of primary fibrinous adhesions) and antibiotics.

Depending on what (except for loose adhesions) which adhesions caused the incarceration of the intestine (omental adhesions, planar, cord-like, multiple), the principle of operative laparoscopic adhesiolysis was to excise or separate adhesions that were dense in consistency between two coagulated areas of collagen tissue. In the case of omental

Journal of Coastal Life Medicine

adhesions, coagulation and resection of the omentum were additionally performed within healthy tissue.

Table 1 Evaluation by the degree of prevalence and type of adhesive process (main group n =111)

Type of adhesions	The prevalence of the adhesive process					
	O.I Blinnikov (1993)					
	1 degree	2 degree	3 degree	4 degree	Total	
abs					%	
planar	-	13	19	1	33	29,8
Corded	-	11	33	5	49	44,1
Stuffing box	-	12	15	2	29	26,1
Total	-	36	67	8	111	100.0

Based on the results of laparoscopic adhesiolysis, we carried out a quantitative characteristic of adhesions according to the degree of prevalence of the process and the type of adhesions (classification of Blinnikova O.I., 1993), which is shown in table.1

As can be seen from the table in our observations, the fact of the presence of cord-like adhesions 44,1% and their combination was more often stated.

When comparing the indicators of coagulological analyzes in patients with the use of FLS during laparotomic and laparoscopic adhesiolysis, a clear difference was noted from the indicators of hemostasis in traditional interventions without the use of FLS. Despite the use of FLS, during laparotomic adhesiolysis, hypercoagulation was noted during the operation of 164.8 ± 1.6 sec, and during laparoscopic intervention, normocoagulation of 212 ± 1.8 sec was noted ($P < 0.05$).

In the first and subsequent days after surgery, hypocoagulation was observed in the control group, moderate hypocoagulation in the main group (313 ± 3.4 sec and 226 ± 3.8 sec, respectively).

Thus, pronounced inflammatory changes in the abdominal cavity cause a sharp violation of both the functional state of vital systems and organs and coagulogram parameters, expressed by hyperfibrinogenemia and inhibition of fibrinolysis.

These data once again testify to the need for sparing surgical interventions for the purpose of early

prevention of SBP. FLS dissolves fibrin threads, normalizes fibrinolysis, thereby preventing the formation of a favorable background for the adhesive process.

For early prevention of the adhesive process in the abdominal cavity, it is necessary to perform a less traumatic laparoscopic surgical intervention, as well as to correct the concentration of fibrinogen and fibrinolytic activity of the blood, with the introduction of FLS, which prevents the development of the adhesive process in the abdominal cavity.

4. Results of Laparoscopic Adhesiolysis in the Early Postoperative Period.

In the immediate postoperative period in children operated on by laparoscopic adhesiolysis, the physical activity of patients was restored several times faster than in the control group. In particular, already a day later, the vast majority of patients were sitting on the bed, moving around the intensive care unit and independently serving themselves, when those operated on by the traditional method began to become more active at best 3-4 days after the operation. Feeding of patients undergoing laparoscopic adhesiolysis began after the first 6-12 hours after the operation.

As can be seen from Table 2, there is no significant difference between the first two compared control groups of patients. Significant differences ($P < 0.05$) in terms of physical activity, terms of feeding and stay of the patient in the ICU and in general inpatient

Journal of Coastal Life Medicine

treatment were noted in the group of patients operated laparoscopically, which once again confirms the

effectiveness of the chosen tactics of surgical treatment and management of patients with AAIO.

Table 2 Comparative characteristics of the restoration of physical activity patients after surgical treatment in the compared groups

Postoperative observations	Operative methods of treatment of ASCI		
	Laparotomy adhesiolysis without FLS (n =20)	Laparotomy adhesiolysis + FLS (n=29)	Laparoscopic adhesiolysis + FLS (n =111)
Duration of surgery (min)	114.2±8.4	105.6±4.6	60.2±0.9**
Physical activation of the patient (days)	5.6±0.6	4.0±0.8	1.6±0.3**
Feeding in (hour)	48-72	48-72	6-10***
Length of stay in the ICU (days)	4.5±0.1	3.5±0.14	1.5±0.02**
Duration of the hospital treatment period, bed-days	10.4±1.2	8.2±0.8	6.0±0.5*

Note: * - differences relative to the data of group 1 are significant (* - P <0.05, ** - P <0.01, *** - P <0.001), ^ - differences relative to the data of group 1 are significant (^ - P <0, 05, ^^ - P <0.01, ^^ - P <0.001)

After laparoscopic intervention, the patients had no complications from the postoperative wound (suppuration, suture divergence, ligature fistulas, etc.). Significantly reduced the length of stay of the patient in the hospital (1.36 times). In the postoperative period, the most important place was given to the early activation of patients and the restoration of intestinal motility.

A comparative evaluation of the results of the treatment of AAIO in three groups of patients convincingly proves the continuity and effectiveness of our proposed tactics for the treatment of AAIO in children. The effectiveness of laparoscopic adhesiolysis against the background of irrigation of the abdominal cavity with FLS is clearly visible, in which not only the number of complications decreases, but physical activity is also restored faster.

The medical and social effectiveness of the developed treatment program is due to: 1) reduction in the length of stay of patients in the hospital, by 1.36 times; 2) a

decrease in the frequency of repeated hospitalizations from 36.8% to 7.5%.

Based on our observations, we came to the following conclusion: laparoscopic adhesiolysis using FLS is a pathogenetically less traumatic method that plays a major role in the early prevention of adhesions in the abdominal cavity; excellent lighting, clear visualization of the organs in the abdominal cavity and their changes allows you to clearly determine the type of adhesions and choose the necessary treatment tactics.

Based on our observations, we were convinced that early prevention of adhesions in the abdominal cavity should be started intraoperatively and continued in the early postoperative period. It is necessary to increase the fibrinolytic activity of the blood, to reduce the concentration of fibrinogen under the control of coagulological changes in the blood, which is facilitated by PL C . The analysis of traditional and minimally invasive surgical treatment of patients with

Journal of Coastal Life Medicine

AAIO gave us the opportunity to develop a specific tactic for preventive measures of adhesive disease in children.

Such tactics of endovisual laparoscopic adhesiolysis allows in the immediate postoperative period to effectively counteract the recurrence of the adhesive process in the abdominal cavity.

Of no small importance is the well-being of the patient in the early postoperative period, the quality of life of the patient and has a good cosmetic effect.

In the main group of patients with the use of laparoscopic adhesiolysis and FLS, suppuration of the postoperative wound, intra-abdominal purulent-inflammatory processes with wound suture failure were not observed in any case. Significantly reduced the length of the patient's stay in the hospital in the postoperative period - by 6.0 ± 0.5 k/days.

Our observations show that the recovery of physical activity of patients after laparoscopic adhesiolysis

with the use of FLS in the immediate postoperative period occurs approximately 3.5 times faster (5.6 ± 0.6 and 1.6 ± 0.3 days, respectively).

Significant injury to the parietal and visceral peritoneum caused by laparotomy, in combination with its inflammation, in AAIO, contributes to the recurrence of adhesion formation! Laparoscopic access minimizes these negative processes as much as possible. The use of the most sparing serous cover of the intestine and the capsule of parenchymal organs of low-traumatic technique (with the use of intraoperative FLS) is one of the main components of the prevention of SB. Thus, according to the results of our study, the use of video-laparoscopic adhesiolysis in combination with an anti-adhesion barrier FLS was successful in 92.7% of cases, in 12 (10,8%) cases, due to technical difficulties, a conversion was performed, the traditional surgical tactics for the treatment of AKI, in 2 case (1,8%), the disease recurred in the long-term period and repeated laparoscopic adhesiolysis was performed.

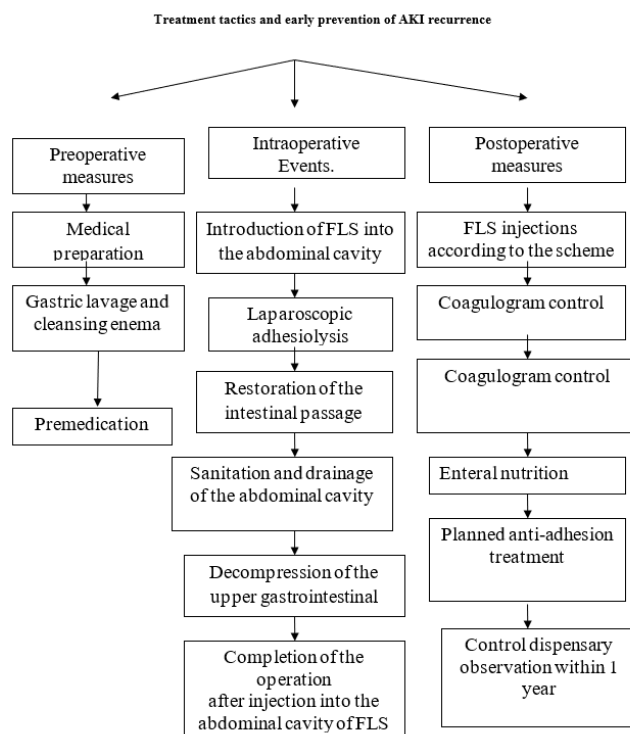


Fig.1. Algorithm for the management of patients with AAIO before, during and in the postoperative period.

Based on the study, we have developed an algorithm for the treatment and early prevention of AKI recurrence in children, which is divided into 3 phases (preoperative, intraoperative and postoperative

measures). Each phase is divided into sub-phases (Fig. 1).

Journal of Coastal Life Medicine

The laparoscopic technique of adhesiolysis, in comparison with the traditional one, allows delicate treatment of tissues and minimizes surgical trauma, which is impossible to achieve with traditional interventions. The foregoing is an effective prevention of the adhesive process in the future.

Thus, according to the results of our study, the use of minimally invasive video-laparoscopic adhesiolysis and anti-adhesion barrier FLS makes it possible to effectively counteract the development of adhesions in the abdominal cavity in the immediate postoperative period.

5. Conclusions:

1. One of the main etiological risk factors for the development of adhesive disease and its complications is the traumatic nature of the traditional "open" primary surgery for inflammatory diseases of the abdominal cavity and the lack of effective means of intraoperative early prevention of adhesions in the abdominal cavity in children.
2. When performing surgical interventions in the abdominal cavity, it is necessary to control the concentration of fibrinogen, on which the activity of the fibrinolysis process depends, which is one of the regulatory links in the pathogenesis of adhesive disease in children.
3. Laparoscopic adhesiolysis with irrigation of the abdominal organs with FLS normalizes the processes of fibrinolysis and the concentration of fibrinogen, effectively reduces the likelihood of postoperative adhesion formation and is a method of early prevention of adhesive disease in children.
4. The use of the developed algorithm for the surgical treatment of AAIO in children allows reducing the risk of re-adhesion formation, reducing recurrence by 3.3 times, reducing the time of surgical intervention, early restoration of the patient's physical activity, reducing the duration of inpatient treatment by 1.6 times, improving the quality of life and obtaining a good cosmetic result. Effect.

Bibliographic References

- [1] Timofeev M.E., Shapovalyants S.G., Larichev S.E. Long-term experience in the use of urgent

video-laparoscopic interventions in acute adhesive small bowel obstruction. Collection of abstracts of the XI Congress of Surgeons of the Russian Federation. 2011;336-337.

- [2] Shapovalyants S.G., Larichev S.E., Timofeev M.E. Laparoscopic interventions for acute adhesive small bowel obstruction. *Endoscopic surgery.* 2013;4:3-8 .
- [3] V.A. Gulyaev "Impaired hemostasis and its correction during operations on the liver" (literature review). *Journal of Annals of Surgical Hepatology.* M. 2005 No. 1 pp. 122-130.
- [4] Lazarenko V.A., Lipatov V.A. Modern semiotics of acute adhesive intestinal obstruction. *Bulletin of Experimental and Clinical Surgery.* 2012;5:2:292-296 .
- [5] Baranov G.A., Karbovsky M.Yu. Comparative assessment of the quality of life of patients operated on for adhesive intestinal obstruction. *Surgery. Journal them. N.I. Pirogov.* 2012;9:70
- [6] Boyko, V.V. Modern aspects of prevention and treatment of patients with adhesive disease of the peritoneum and its complications / V.V. Boyko, I.A. Taraban, V.G. Groma and others // *Kharkov School of Surgery.* - 2013. - No. 2. - P. 122-128.
- [7] Akramov, E.Kh. Prevention of early acute intestinal obstruction in destructive forms of the appendix / E.Kh. Akramov, K.V. Ruchkina // *Medicine and education in Siberia.* - 2014. - No. 2. - P. 35 .
- [8] O'Connor D, Winter D. The role of laparoscopy in the management of acute small-bowel obstruction: a review of over 2,000 cases. *Surg Endosc.* 2012;26:12-17 .
- [9] Di Saverio S, Coccolini F, Galati M e t al. Bologna guidelines for diagnosis and management of adhesive small bowel obstruction (ASBO): 2013 update of the evidence-based guidelines from the world society of emergency surgery ASBO working group. *World Journal of Emergency Surgery.* 2013;8:1:42 .