

Case of Aggressive Odontogenic Keratocyst Involving Maxillary Sinus: A Case Report and Review of Literature

Received: 17 August 2022, **Revised:** 13 September 2022, **Accepted:** 15 October 2022

Dr. Ridhi Matariya,

Professor and Head, Department of Oral and maxillofacial Surgery, Karnavati School of Dentistry, Karnavati University, Gandhinagar, Gujarat, India. Orcid id: 0000-0002-3237-634X

Dr. Parth Parikh

Senior Lecturer, Department of Oral and maxillofacial Surgery, Karnavati School of Dentistry, Karnavati University, Gandhinagar, Gujarat, India. Orcid id: 0000-0003-1025-623X

Dr. Ekta Mistry

Reader Department of Oral and maxillofacial Surgery, Karnavati School of Dentistry, Karnavati University, Gandhinagar, Gujarat, India. Orcid id: 0000-0001-8883-8809

Dr. Charu Sharma,

Consulting Dental Surgeon, Ahmedabad, Gujarat, India. Orcid id: 0000-0001-5283-411X

Dr Kartik Vadhel

Senior Resident, Department of Oral and maxillofacial Surgery, Karnavati School of Dentistry, Karnavati University, Gandhinagar, Gujarat, India. Orcid id: 0000-0002-4419-4121

Dr. Jeemee Patel

Department of Oral and maxillofacial Surgery, Karnavati School of Dentistry, Karnavati University, Gandhinagar, Gujarat, India. Email ID: Jimmy.patel111@yahoo.com

Keywords

Odontogenic keratocyst, Odontogenic keratocyst involving maxillary sinus, Nasal antrostomy, enucleation, marsupialization

Abstract

Odontogenic Keratocysts (OKC) are invasive and aggressive cyst present in either maxilla or mandible. They are present more commonly in mandible- posterior region. They are also found in maxilla- in canine region. Involvement of maxillary sinus is very rare. We present here a rare case of OKC involving maxillary sinus and treated by enucleation followed by chemical cauterization with Carnoy's solution. In histological report we found corrugated layer of parakeratinized stratified squamous epithelial lining.

1. Introduction

Odontogenic keratocysts first described by Philipsea in 1956 are benign intraosseous lesion of odontogenic origin [1]. OKC is having high chances of recurrence and they are considered as highly invasive lesion. [3]. WHO in 2017 reclassified

odontogenic keratocysts and placed into cystic category [4]. It accounts 4-12% of all jaw cyst. It is often asymptomatic, accidentally diagnosed on x-ray, may cause swelling and symptoms of discharge [2]. Mandible is most commonly involved (60-70%) than maxilla (30%) with rare involvement (1%) of maxillary sinus. [5]. There are different

treatment modalities to treat OKC which involves simple enucleation, decompression or marsupialisation followed by enucleation, en block resection and use of chemical agents like Carnoy's solution and 5-FluoroUracil.

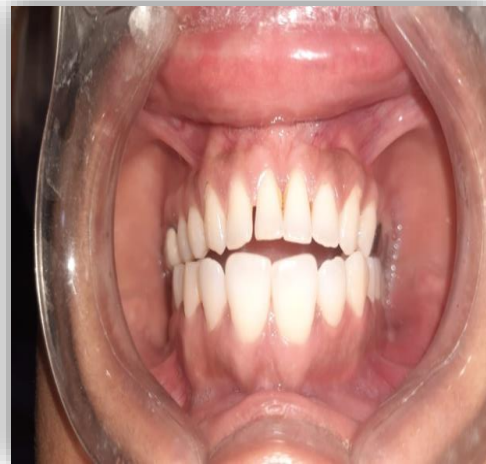2. Case Report

A 41 year old female reported with chief complaint of pain and swelling in upper right teeth back region since last 1 month and with was gradually increased since last 10 days and felt dull etching pain. Before 6 months patient had undergone for removal of right wisdom tooth. Diffuse swelling was present on right

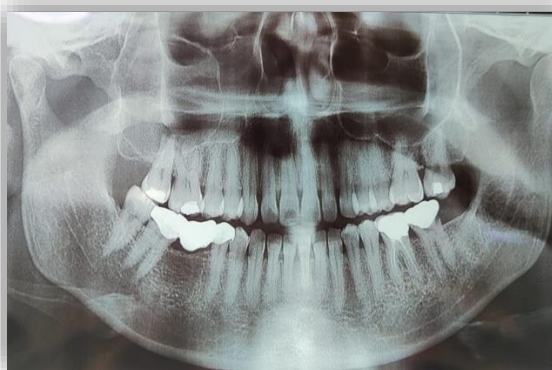cheek region and extending zygomatic arch to lower border of mandible supero-inferiorly and from ala of the nose to tragus antero posteriorly. On palpation it was soft and tender. On intraoral examination; a vestibular obliteration was seen on the right upper first premolar to third molar area. No pus discharge and sinus tract present. Radiographic examination shows that unilocular well define expansile lytic lesion is seen in maxilla on right side which extends to right maxillary sinus. It extends antero posteriorly from 1st molar tooth to maxillary tuberosity. The lesion measures approximately 3.2(AP)* 2.7(TR)* 3.3(CC).



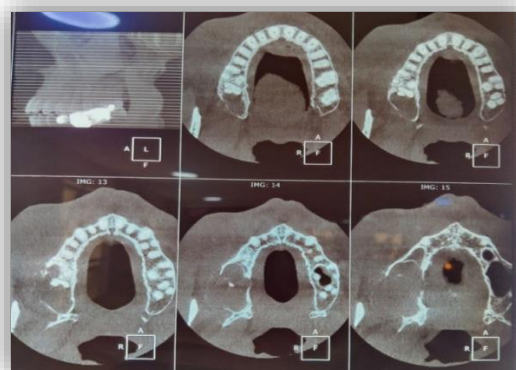
(a)



(b)

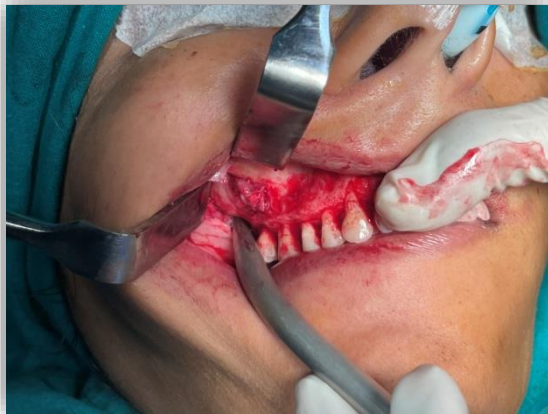

(c)

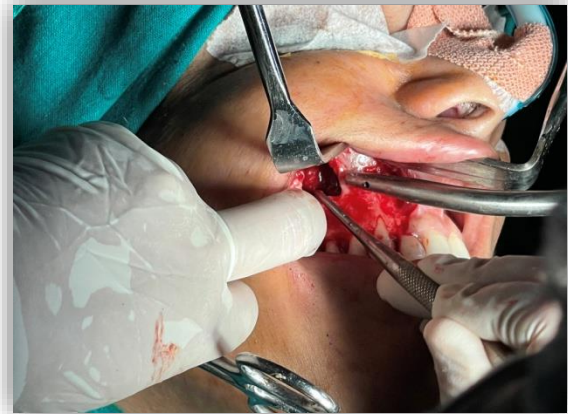

(d)

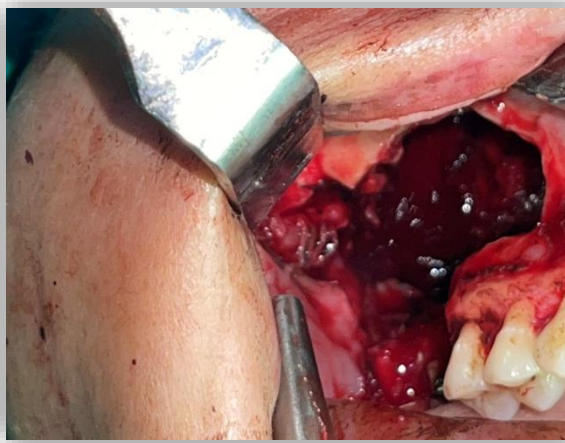
Figure 1. (a,b) Pre-Operative Clinical Photograph and (c,d) Radiograph, OPG and Ct Scan (axial section)



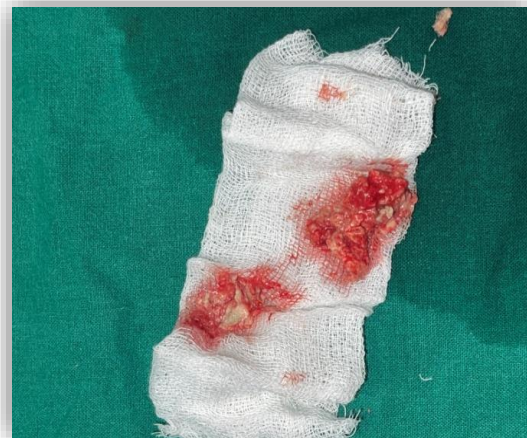(a)



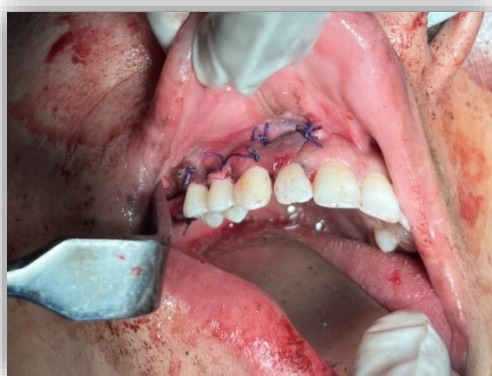(b)



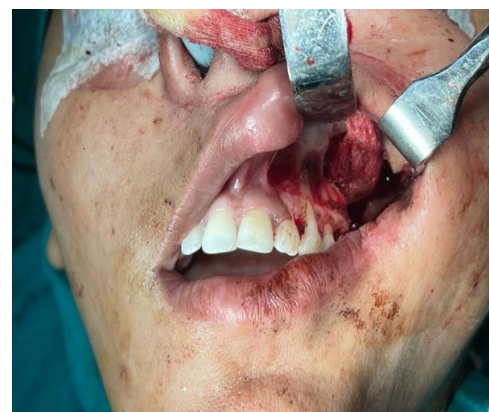(c)



(d)



(e)



(f)

Figure 2 (a) incision and mucoperiosteal flap elevation (b) bony window creation (c,d) enucleation of the lesion (e) closure with vicryl suture. (f) nasal antrostomy Surgical Procedure

Patient was operated under general anaesthesia. Crevicular incision extending from maxillary right

lateral incisor to second molar and relieving incision was placed on both sides. Full thickness

Journal of Coastal Life Medicine

mucoperiosteal flap was reflected, bony perforation was observed in between first and second molar region. A bony window was then created for enucleation of the lesion. The lesion was then separated from the adjacent bone and then removed. On aspiration a cheese like material was observed. All the bony margins were checked and all the soft tissue were excavated with the help of a curette. Application of Carnoy's solution was done for 30 seconds followed by irrigation of bony cavity with Betadine. Nasal antrostomy was performed. 3-0 vicryl sutures were used for closure in interrupted manner.

3. Discussion

The odontogenic keratocysts are developmental in origin. They frequently derived from remnants of dental lamina.[4] This lesion is more commonly present in mandibular posterior region followed by maxillary posterior region and canine region, rarely involving maxillary sinus. [2] Breach in Schneiderian membrane due to odontogenic pathology involving maxillary bone may result in maxillary sinus pathology. [6]. Etiology of cystic lesions involving maxillary sinus can be odontogenic or non-odontogenic. In odontogenic causes, it may be developmental or inflammatory and in non-odontogenic etiology it may be due to foreign body, some trauma, and chronic maxillary sinusitis or as post-surgical complication. [1]. We can differentiate this lesion from odontogenic cysts through radiological evaluation like CBCT or CT scan [1]. Patients having OKCs usually have complain of pain, swelling, pus discharge. It can create paresthesia of adjacent regions to when the lesion becomes larger in size.[6]

Characteristic histopathological features of OKCs are: a desquamated epithelial cystic lining, thick

lining of Para keratinized stratified squamous epithelium (6-10 cells) with palisading basal cell layer of even thickness is seen[6]. OKCs can be histologically either parakeratinized or orthokeratotic. Out of these two variants, parakeratinized variant is more aggressive and having more recurrence than orthokeratinized variant [1,3]

OKC can be treated by various methods like enucleation, curettage, marsuiplication, use of chemical agents like Carnoy's solution. Ohter treatment method 5FU, cryotherapy with liquid nitrogen or peripheral osteotomy and surgical resection of the lesion. [6] The choice of treatment is decided on various factors which include age, size and recurrence. Lesion involving vital structures can be treated with marsupialization or decompression followed by enucleation procedure, and recurrent lesion can be treated by en bloc resection as it provides 0 to 1% recount rate after treatment.

In literature small lesions are treated with enunciation curettage followed by chemical cauterization. Large lesions are treated with marsupialization, enucleation, and chemical cauterization. Long term follow up needed after treatment of OKS because of high recurrence rate. In our present case, OKC was completely restricted to maxillary sinus and not involving alveolar process of maxilla. So we had done the enucleation through Caldwell-Luc approach followed by chemical cauterization, histological report shows that corrugated layer of parakeratinized stratified squamous epithelial lining. With a few orthokeratinized layers. Epithelial lining approximately 6-8 cells layered thick and has flat epithelial.

AUTHOR	YEAR	TREATMENT DONE	AGE & GENDER
Absi et al,	1994	Marsupialization followed by enucleation after 10 months	Case 1 21/female Case 2 : 52/female
Carvalho Silva et al,	2005	Enucleation & Curettage	Case1 17/male Case 2 14/male

Journal of Coastal Life Medicine

Abhishek Gupta et al,	2011	Enucleation & Curettage	64/female
Kim et al,	2011	Enucleation, Curettage	85/female
Yadav et al,	2013	Enucleation, Curettage, Carnoy's solution	16/female
Jianhua et al	2014	Enucleation, curettage and cryotherapy	25/male
Nahvi et al	2016	Enucleation, Curettage	15/male
Sanika Kulkarni	2017	Enucleation, Curettage, Carnoy's solution	42/male
Srikanth Gadicherla et al,	2018	Enucleation, Curettage, Carnoy's solution	21/male
Madhusudhan R. Madhireddy et al	2018	Enucleation, Curettage	8/ male
Muhammad Jamal	2019	Marsupialization Followed by Enucleation and Chemical Cauterization	22/male
H S Sheethal et al,	2019	Enucleation, antrostomy	15/female
Mitsuo Goto et al,	2020	Enucleation, Curettage	21/male
Michael Walsh	2022	maxillary antrostomy, Marsupialization	29/female

4. Conclusion

OKC in maxillary sinus is rare. Parakeratinized OKC has high recurrence rate compare to orthokeratinized. It is generally asymptomatic and cause swelling and pus discharge at later stage. Early diagnosis with clinical, radiographic and histological examination is at most important. Treatment plan very according to size of the lesion and involvement of vital structures. Recurrence rate was found to vary from 0% to about 62%, depending on the kind of treatment management. Long term follow up is required.

References:

[1]Gadicherla S, Kamath AT, Dhara VB, Smriti K. Keratocystic Odontogenic Tumor Involving

Maxillary Antrum. Online J Health Allied Scs. 2017;16(4):15. Sheethal HS, Rao K, Umadevi HS, Chauhan K. Odontogenic keratocyst arising in the maxillary sinus: A rare case report. J Oral Maxillofac Pathol 2019;23:S74-7.

[2]Walsh M, Hussein MA, Carter M, Abdulrahman S. Maxillary Odontogenic Keratocyst. J Surg Case Rep. 2022 Apr 11;2022(4):rjac078. doi: 10.1093/jscr/rjac078. PMID: 35422993; PMCID: PMC9004408.

[3]Kulkarni S, Nilesh K, Patil P, Parkar M, Kamla Ka, Large Keratocystic Odontogenic Tumor involving entire maxillary sinus: A common pathology in uncommon location. IP Int J Maxillofac Imaging 2017;3(2):68-70

[4]Goto M, Ueda S, Miyabe S, Watanabe S, Sugita Y, Nagao T. A rare case of odontogenic keratocyst

Journal of Coastal Life Medicine

- extending into the sphenoid bone from the maxilla. *Int J Surg Case Rep.* 2020;71:132-138. doi: 10.101/j.ijscr.2020.05.003. Epub 2020 May 21. PMID: 32446993; PMCID: PMC7256210
- [5] Jamal M, Baig MZ, Saher L, Asim M, Ahmed M. Marsupialization followed by enucleation and chemical cauterization for treatment of odontogenic keratocyst involving maxillary sinus: A Case Report. *J Islamabad Med Dental Coll.* 2019; 8(4):208-212.
- [6] Absi EG, Sim RL. Odontogenic keratocyst involving the maxillary sinus: report of two cases. *Dentomaxillofac Radiol.* 1994 Nov;23(4):226-9. doi: 10.1259/dmfr.23.4.7835529. PMID: 7835529.
- [7] Gupta A, Rai B, Nair MA, Bhut MK. Keratocystic odontogenic tumor with impacted maxillary third molar involving the right maxillary antrum: An unusual case report. *Indian J Dent Res* 2011;22:157-60
- [8] Kim DJ, Kim SD, Kim SH, Cho KS. Endoscopic Removal of Huge Cholesterol Granuloma in the Maxillary Sinus Confused With Odontogenic Keratocyst. *J Craniofac Surg.* 2020 Mar/Apr;31(2):507-509. doi: 10.1097/SCS.00000000000006199. PMID: 31895863.
- [9] Yadav, Santosh Kumar. Conservative approach to a large keratocystic odontogenic tumor of maxillary sinus: a case report. *Egyptian Journal of Oral & Maxillofacial Surgery: April 2013 - Volume 4 - Issue 2 - p 41-46* doi: 10.1097/01.OMX.0000428187.48823.8c
- [10] Zhou J, Wang L, Chen Z, Qiu J, Dong Q. Giant keratocystic odontogenic tumor of the maxillary sinus and zygoma: A case report. *Oncol Lett.* 2014 Dec;8(6):2675-2677. doi: 10.3892/ol.2014.2576. Epub 2014 Sep 29. PMID: 25364448; PMCID: PMC4214464.
- [11] Mohajerani, H., Pakravan, A. H., Aghdashi, S. F., Nahvi, G., & Motamedian, S. R. (2016). Bilateral Keratocystic Odontogenic Tumor Invading Maxillary Sinuses: A Case Report. *Journal of "Regeneration, Reconstruction & Restoration"* (Triple R), 1(2), 90-93. <https://doi.org/10.22037/rrr.v1i2.10515>