

## Management of Chronic Osteomyelitis in Post Covid Cases - A Case Report

**Received:** 12 February 2023, **Revised:** 14 March 2023, **Accepted:** 16 April 2023

**Dr. Anil Managutti<sup>1</sup>, Dr. Ujval Bhavsar<sup>2</sup>, Dr Nirav Patel<sup>3</sup>, Dr Bansari Ajagia<sup>4</sup>, Dr Parth Suthar<sup>5</sup> Dr Dharmik Parmar<sup>6</sup>**

1. HOD & Professor, Department of Oral & Maxillofacial Surgery, Narsinhbhai Patel dental college and hospital, Sakalchand patel university, Visnagar, India. Dranilman12@gmail.com 9727756155

2. MDS postgraduate student, Department of Oral & Maxillofacial Surgery, Narsinhbhai Patel dental college and hospital, Sakalchand patel university Visnagar, India. ujjvalbhavsar@gmail.com 8490088909

3. Senior Lecturer, Department of Oral & Maxillofacial Surgery, Narsinhbhai Patel dental college and hospital, Sakalchand patel university, Visnagar, India. Dr.nirav8@gmail.com 9409561271

4. MDS postgraduate student, Department of Oral & Maxillofacial Surgery, Narsinhbhai Patel dental college and hospital, Sakalchand patel university, Visnagar, India. bansariajagia@gmail.com 9427119479

5. Senior Lecturer, Department of Oral & Maxillofacial Surgery, Narsinhbhai Patel dental college and hospital, Sakalchand patel university, Visnagar, India. Parth.suthar410@gmail.com 6353088720

6. MDS postgraduate student, Department of Oral & Maxillofacial Surgery, Narsinhbhai Patel dental college and hospital, Sakalchand patel university Visnagar, India. Parmardharmik868@gmail.com 8140548044

### Keywords:

Fungal Osteomyelitis of Maxilla, Maxillectomy, Fungal osteomyelitis, Rhinomaxillary Fungal osteomyelitis

### Abstract

Fungal osteomyelitis, an emerging angioinvasive infection caused by ubiquitous filamentous fungi of the order Mucorales. Fungal osteomyelitis has emerged as the third most common invasive mycosis and is important in hematologic and allogeneic stem cell transplantation, following candidiasis and aspergillosis. Fungal osteomyelitis continues to be a problem in diabetes (DM) in Western countries. Similarly, in developed countries such as India, this condition has received less and less attention, especially in patients with uncontrolled diabetes and trauma. Recently, during this Covid-19 period, there has been a surge in disease in the post-Covid stage in immunocompromised cases requiring long-term treatment with corticosteroids and ventilators. The purpose of this case report is to highlight the feasibility of a bona fide surgical intervention. Surgery offers predictable options through proper case selection and surgeon expertise. We present the case of a 65-year-old man with extensive maxillary osteomyelitis and later diagnosed as maxillary fungal osteomyelitis.

### 1. Introduction

Fungal osteomyelitis is a disease of the craniomaxillofacial region which is spread through the fungus called the Mucorales. The fungus invades blood vessels and clots within it and causing impaired blood circulation and causing the bone necrosis or dead bone or sequestrum formation. It can be aggressively spreading infection which is associated with the diabetes and long term steroidal therapy, neutropenia, blood malignancy, organ transplantation, malnutrition, burns and immunosuppressive therapy [2].

The most common form is Rhinocerebral fungal osteomyelitis that affect the paranasal sinuses, maxilla, orbit, and possibly the brain of the craniomaxillofacial region. Clinical presentation of this includes orbital and maxillary cellulitis, dead

bones, or crusting of body cavities or palate with occasional pus discharge, nasal congestion, halitosis and usually dull aching pain reported. Ophthalmoplegia and loss of vision indicate disease aggression and progression. Intracranial complications of fungal infection includes occipital and frontal lobe infarctions, cavernous sinus or sagittal sinus thrombosis. This is associated with very high mortality rate [3].

Many patients showed dry socket after extraction with very high mortality rate but early clinical diagnosis & intervention makes the higher chances of survival.

This article presents the case of a 65-year-old male patient who had a complain of extensive maxillary osteomyelitis and was later diagnosed with maxillary fungal osteomyelitis. The proposed treatment plan consisted of a total maxillary bone removal surgery

and bilateral sinus debridement under general anesthesia.

## 2. Case Report

A 65-year-old male patient presented to an oral and maxillofacial surgery clinic complaining of maxillary tooth movement for 20 days. Ease of movement is accompanied by continuous discharge of pus, swelling of the gums and swelling of the face. He then noticed occasional bleeding from swollen gums and heavy breathing from the same area. The patient had a history of ischemic heart disease 4 years ago and was regularly medicated, had a cardiac stent placed 4 years ago, had diabetes and drug use in the previous 2 months, and had been diagnosed with Covid-19 2 years ago. Has a history of illness, is recovering in home care, and has a subsequent history of illness. He had a severe headache (occipital and frontal) 2 months ago and was hospitalized for 6 days. Clinical examination revealed mobility of all maxillary teeth, multiple sinus ducts with pus draining over the maxillary gingiva, and slight diffuse extraoral swelling that was painful on palpation. Radiological examination with CT scan revealed bilateral sinus

mucosal thickening and hard palate, bilateral maxillary alveolar bony erosion, ground-glass opacification of both orbital wall and lateral pterygoid, and possible fungal sinusitis. A change has become apparent. All biochemical tests were within normal limits. A diagnosis of “maxillary fungal osteomyelitis” was made based on medical history, laboratory and radiological examinations. The final diagnosis was maxillary and maxillary sinus fungal osteomyelitis. A total maxillary resection with debridement of the bilateral maxillary sinuses under general anesthesia was proposed as the treatment plan.

After taking consent, he was planned for debridement under General anaesthesia. On surgical exposure, all the maxillary involved teeth extracted, The entire sequestrectomy the lining of the both maxillary sinuses were removed. Primary closure was subsequently performed. Post operative recovery was uneventful. The Patient was administered tab **Posaconazole 200mg TDS for 3weeks** under close monitoring. After 2 weeks the wound healing was found satisfactory. Even after 1 month from the surgical intervention no recurrence of any kind has been reported.

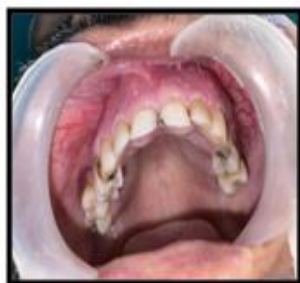

Figure: 1

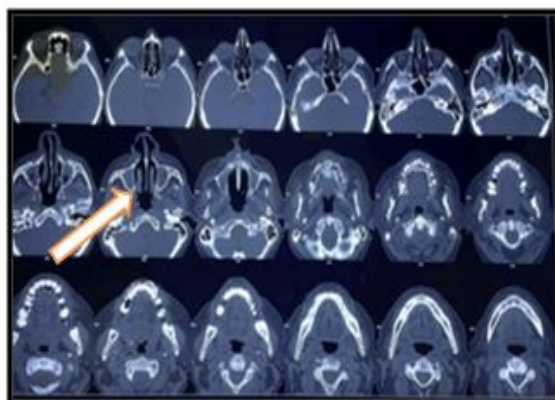


Figure: 2

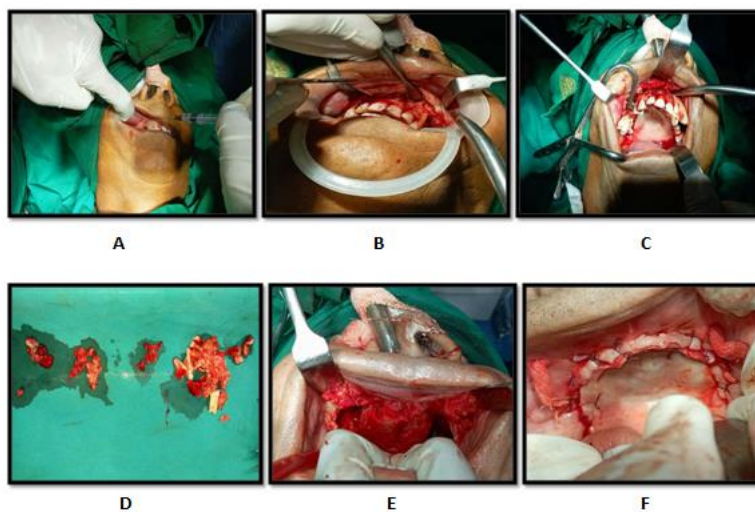


Figure : 3

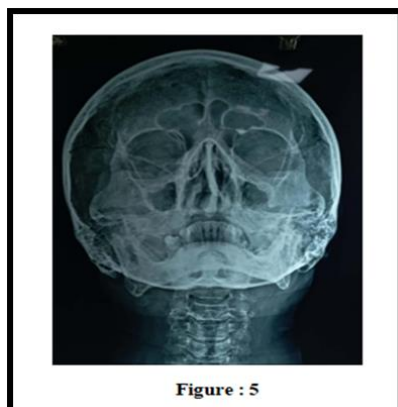


Figure : 5

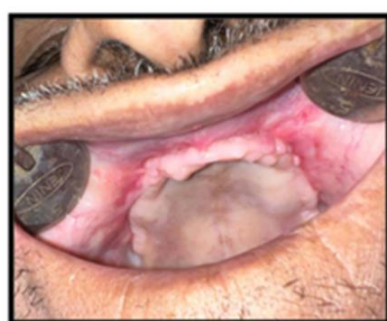

Figure : 4

**Figures :-** (1) Pre-operative Intraoral Photographs shows multiple fistula and oedematous palate, (2) Pre-Operative CT Scans showing bony erosion and sinus obliterations, (3A) Local anesthesia given, (3B) Incision Given, (3C) Surgical site Exposure, (3D) Sequestrectomy and total Maxillectomy, (3E) Bilateral Maxillary sinus debridement, (3F) Surgical

Site Closure, (4) Follow- Up After 1 year, (5) Follow Up radiograph

### 3. Discussion

Partauf is believed to have made the first histological description of systemic fungal osteomyelitis in



# Journal of Coastal Life Medicine

patients over the age of 52 in 1885. A fungal osteomyelitis (also called phycomycosis or zygomycosis) seen most commonly in the immunocompromised people, which often caused by non-septic fungus of the Zygomycota, but has now been superseded by the phylum Zygomycota [4]. The disease was transmitted by inhaling spores. The three genera *Rhizopus*, *Absidia*, and *Mucor* are the genera most commonly involved in this. *Rhizopus* is the major causative agent and accounts for 90% of rhinoencephalofungal osteomyelitis cases.

Based on clinical appearance it is classified into six groups:

Skin, dissemination, lung, gastrointestinal, gastrointestinal, etc. Nasocephalic is the most common type (44–49%), followed by cutaneous (10–15.5%), pulmonary (10–11%), disseminated (6–11%), and gastrointestinal (2 cases-11%) [5].

A subtype of the rhinocerebral type, rhinomaxillary disease, develops when a susceptible person inhales the fungus. Infection begins in the nose and sinuses and can spread through blood vessels or directly into the eye sockets and brain tissue. Once the fungus invades arteries, it induces thrombosis and causes necrosis of both hard and soft tissues [6].

Phagocytes of immunocompetent hosts produce defensins (cationic peptides) that are used to destroy mucospores [7]. However, transferrin's ability to bind iron is reduced only in uncontrolled diabetic ketoacidosis, leading to elevated blood iron levels, which *Mucor* successfully exploited to grow in this way [8].

62.5% cases of rhinocerebral form and 100% of disseminated form are seen with prevalence rate of more than 50%. High morbidity and mortality rate is seen because of rapid vascular invasion that can cause tissue necrosis and because of infarction. Survival chances for patients with fungal osteomyelitis range from fifty to eighty-five percentages with having higher chances of living in rhinocerebral disease compared to pulmonary or disseminated disease. The prognosis is fairly good if the disease has not spread outside the sinuses [10]. With drug therapy alone, mortality ranges from 39% to 70%, while surgical debridement reduces mortality to 55% to 27% [11]. The cornerstone of effective treatment is aggressive

treatment with conventional antifungal drugs. The two main treatments for fungal osteomyelitis are lipid complexes and amphotericin B deoxycholate. The recommended dose is 0.5 to 1.5 mg/kg once daily for 4 weeks. Serum electrolytes should be carefully monitored as amphotericin B is responsible for potassium imbalance [12]. Improved survival and fewer side effects have been observed with lipid complex amphotericin B in comparison with deoxycholate amphotericin B [13].

In our case, all affected maxillary teeth were extracted. The lining of both maxillary sinuses was removed during the calcaneus excision. Fill both sinuses with gauze bandages soaked in neosporin and betadine ointment. Primary closure was then performed and an intraoral palatal plate was applied. Postoperative recovery was uneventful. The histopathological diagnosis was fungal osteomyelitis, but because it was chronic and low-grade, we decided to treat it with posaconazole alone. The dosage of posaconazole extended release tablets is 300 mg every 12 hours for the first day, then 300 mg once a day until a negative result is obtained. A follow-up was conducted.

Defect rehabilitation can be done with patient-specific implants or cheek implants, but patients could not afford the treatment. As always, prevention is the most important criterion. Maintaining immunological balance is very important to avoid this fulminant disease, especially in immunocompromised people. Tooth extraction in diabetic patients should be done carefully with constant supervision and frequent follow-up.

## 4. Conclusion

Fungal osteomyelitis is a potentially fatal disease that requires early clinical diagnosis as well as accurate and reliable surgical treatment. Posaconazole creates a fail-safe medical regimen that helps patients achieve better outcomes and even halts disease progression.

## References:

- [1] Kumar N, Singh AK, Pandey S, Agrawal S, Singh S. Rhinomaxillary osteomyelitis due to fungal osteomyelitis in an immunocompromised geriatric patient: a case report with review of

# Journal of Coastal Life Medicine

- treatment options. *Egyptian Journal of Oral & Maxillofacial Surgery*. 2015 May 1;6(2):66-70..
- [2] Jagdish C, Reetika S, Pallavi S, Jayanthi S, Divya P, Balasubramanya A. Fungal osteomyelitis of the paranasal sinus with gas forming maxillary osteomyelitis – a case report. *Internet J Microbiol* 2012; 10:1..
- [3] Kontoyiannis DP, Lewis RE. Agents of fungal osteomyelitis and entomophthoromycosis. In: Mandell GL, Bennett JE, Dolin R, editors. *Principles and practice of infectious diseases*, 7th ed. Philadelphia, PA: Churchill Livingstone/Elsevier; 2009.
- [4] Hibbett DS, Binder M, Bischoff JF, Blackwell M, Cannon PF, Eriksson OE, et al. A higher-level phylogenetic classification of the Fungi. *Mycol Res* 2007; 111:509–547.
- [5] Chakrabarti A, Das A, Sharma A, Panda N, Das S, Gupta KL, Sakhuja V. Ten years' experience in zygomycosis at a tertiary care centre in India. *J Infect* 2001; 42:261–266.
- [6] Greenberg MS. Ulcerative vesicular and bullous lesions. In: Greenberg MS, Glick M, editors. *Burket's oral medicine diagnosis and treatment*. BC Decker, Philadelphia: Elsevier; 2003. p. 79.
- [7] Bouza M, Mun˜oz P, Guinea J. Fungal osteomyelitis: an emerging disease. *Clin Microbiol Infect* 2006; 12:7–23.
- [8] Aggarwal P, Saxena S, Bansal V. Fungal osteomyelitis of maxillary sinus. *J Oral Maxillofac Pathol* 2012; 11:66–69
- [9] Brown OE, Finn R. Fungal osteomyelitis of the mandible. *J Oral Maxillofac Surg* 1986; 44:132–136
- [10] Spellberg B, Edwards J Jr, Ibrahim A. Novel perspectives on fungal osteomyelitis: pathophysiology, presentation, and management. *Clin Microbiol Rev* 2005; 18:556–569.
- [11] Lee FY, Mossad SB, Adal KA. Pulmonary fungal osteomyelitis: the last 30 years. *Arch Intern Med* 1999; 159:1301–1309
- [12] Prasad K, Lalitha RM, Reddy EK, Ranganath K, Srinivas DR, Singh J. Role of early diagnosis and multimodal treatment in rhinocerebral fungal osteomyelitis: experience of 4 cases. *J Oral Maxillofac Surg* 2012; 70:354–362.
- [13] Shetty SR, Punya VA. Palatal fungal osteomyelitis: a rare clinical dilemma. *Oral Surg* 2008; 1:145–148