

## Segmental Mandibulectomy and Immediate Reconstruction with Rib Graft in Ameloblastoma: A Case Report

**Received:** 21 February 2023, **Revised:** 26 March 2023, **Accepted:** 28 April 2023

**Dr. Anil Managutti<sup>1</sup>, Dr. Bansari Ajagia<sup>2</sup>, Dr. Shailesh Menat<sup>3</sup>, Dr. Ujjaval Bhavsar<sup>4</sup>,  
Dr. Parth Suthar<sup>5</sup>, Dr. Reema Oza<sup>6</sup>**

<sup>1</sup>HOD & Professor, Department of Oral & Maxillofacial Surgery, Narsinhbhai Patel dental college and hospital, Visnagar, India. Dranilman12@gmail.com 9727756155

<sup>2</sup>MDS postgraduate student, Department of Oral & Maxillofacial Surgery, Narsinhbhai Patel dental college and hospital, Visnagar, India. bansariajagia@gmail.com 9427119479

<sup>3</sup>Professor, Department of Oral & Maxillofacial Surgery, Narsinhbhai Patel dental college and hospital, Visnagar, India. drshailmenat80@gmail.com 9825624905

<sup>4</sup>MDS postgraduate student, Department of Oral & Maxillofacial Surgery, Narsinhbhai Patel dental college and hospital, Visnagar, India. ujjavalbhavsar@gmail.com 8490088909

<sup>5</sup>Senior Lecturer, Department of Oral & Maxillofacial Surgery, Narsinhbhai Patel dental college and hospital, Visnagar, India. Parth.suthar410@gmail.com 6353088720

<sup>6</sup>MDS postgraduate student, Department of Oral & Maxillofacial Surgery, Narsinhbhai Patel dental college and hospital, Visnagar, India. reemaenza94@gmail.com 8238583547

### Keywords:

rib graft, non-vascularized graft, and plexiform ameloblastoma

### Abstract

**Introduction:** An Ameloblastoma is one of the benign tumor that usually develops in the mandible bone. There are various treatment options, such as, Chemical cauterization, curettage, and liquid nitrogen are other options for treating this condition; however, enucleation and surgical cutting (resection) or dredging, remains the utmost effective method. Mandibular defect reconstruction options include free tissue transfer or non-vascularized bone graft following surgical excision.

**Case Study:** We present a case of Fifty-year-old male patient came with the chief complain of swelling & reduced mouth opening in the lower left jaw of the face. While on examination, the left mandibular body area displayed a diffuse, hard and tender swelling. Normal skin covered the swelling. There were bilateral fibrous bands, buccal vestibule obliteration, and mobility of 35-38 teeth. Plexiform Ameloblastoma was found in the biopsy. The tumor was removed and then rebuilt using a reconstruction plate and rib graft.

**Discussion:** When microvascular expertise is lacking, reconstruction using a bone graft that is not vascularized is the best option. In our case, a non-vascularized rib graft was used for reconstruction. In the one-year follow-up period, there were no problems and a favorable shape, symmetry, function, and aesthetic appearance.

### 1. Introduction

An actual neoplasm of the odontogenic epithelium is ameloblastoma (1). It accounts for roughly one percent of all the oral tumors and nine percent of odontogenic origin tumors (2). It is an aggressive neoplasm that develops from dental organ (odontogenic epithelium) and lamina remnants (3). The majority of ameloblastomas occur in the molar region of ramus in the mandible, with 70% rising there, they might occasionally be linked with third molar teeth that have not yet erupted. Ameloblastoma can affect people of any age, including children, but

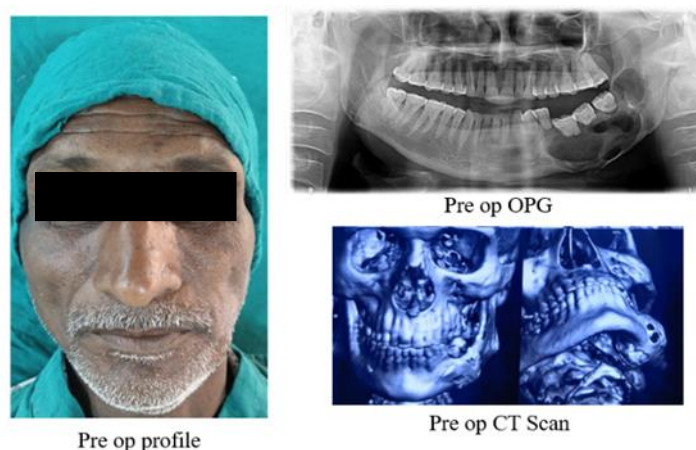
its most common stage is in the third to fifth decade of life. The plexiform and follicular types of ameloblastoma are the most common histopathological variants, followed by the acanthomatous, granular cell subsequent types (5). It is common knowledge that ameloblastoma can exhibit multilocular or unilocular radiolucency with the appearance of a honeycomb or soap bubble on radiographs. The recurrence rate of the plexiform pattern is significantly lower and it is less aggressive. For mandibular reconstruction free flaps is the best now that craniofacial surgical techniques have advanced. Non-vascularized cancellous bone graft from the rib or iliac

crest is still an option in centers without microvascular surgery facilities.

## 2. Case Report

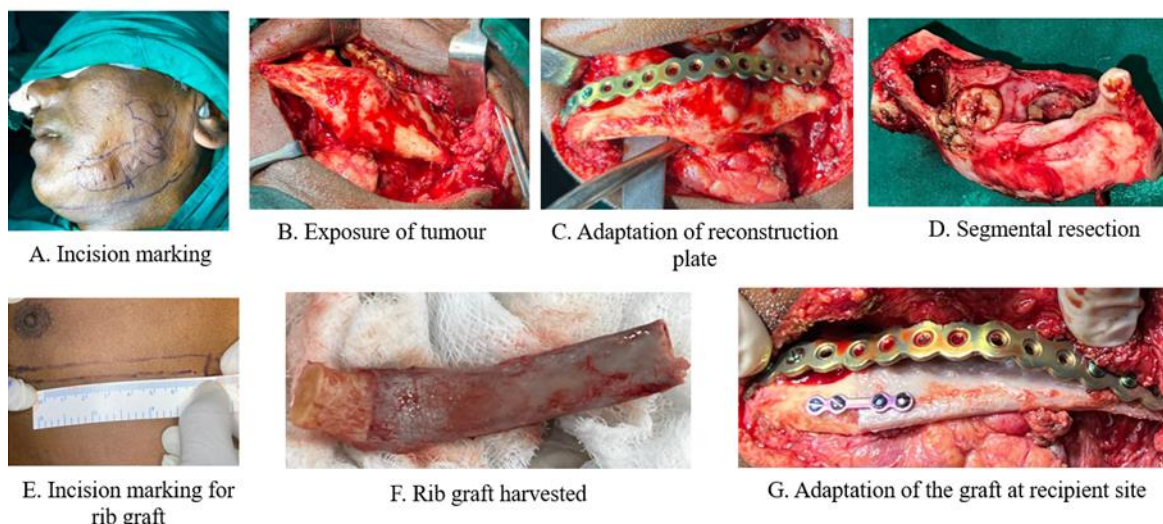
A 50 years old male patient came to oral and maxillofacial surgery department with the chief complain of swelling on left side of face and occasional bleeding from left back teeth region since last two months. The swelling was small and then progressively got bigger in size. Patient also complains of difficulty in eating from past 15 yrs because of reduced mouth opening. (Patient had undergone surgery in the left jaw before 15 years). The medical history was unremarkable. Patient had practice of chewing tobacco 4-5 packets/day for 25 years. On examination a single diffused swelling was seen over the left side of lower jaw region, with approx. two x two cm in size and extending two cm away from corner of the mouth and one cm on the inferior border of the mandible (Figure 1). The swelling is hard and non-tender, with no change in the colour of the skin. Intraorally, Bony expansion was seen on lingual and buccal side in 35,36,37,38 teeth region. There was lingual tipping of 36, 37, 38 along with grade 3 mobility of same teeth. Buccal vestibular obliteration was seen from 35 till 37 teeth. Vertical and horizontal fibrous bands are palpable on the right

and left buccal mucosa with blanching. An orthopantomogram radiograph was done, which showed large multilocular cystic lesion extending from 34 teeth till ramus of mandible. CT scan showed that there was thinned-out cortex and cystic lesion was confined to the mandible. An aspiration biopsy was done which suggested infected cyst. On incisional biopsy, histopathological examination revealed plexiform ameloblastoma. Under nasoendotracheal intubation and general anaesthesia tumour was exposed buccally and lingually. Titanium reconstruction plate was adapted so as to maintain mandibular contour. Following extraction of lower canine, osteotomy cut was set and finished buccally and lingually. As a result, a tumor mass was removed. The contralateral side of the fifth rib was used to harvest the rib graft. It was reshaped and used in the mandible body reconstruction (Figure 2). The valsalvaneuver was performed to examine plural tear. At the recipient and donor sites, haemostasis was attained, the vacuum drain was placed, and layers of closure were performed. Analgesics, anti-inflammatory medications, and antibiotics were administered following surgery. On the tenth day after surgery, sutures were removed due to uneven wound healing. Since then, the patient has been followed up on a regular basis. So far, there had been no reports of a recurrence. (Figure 3).

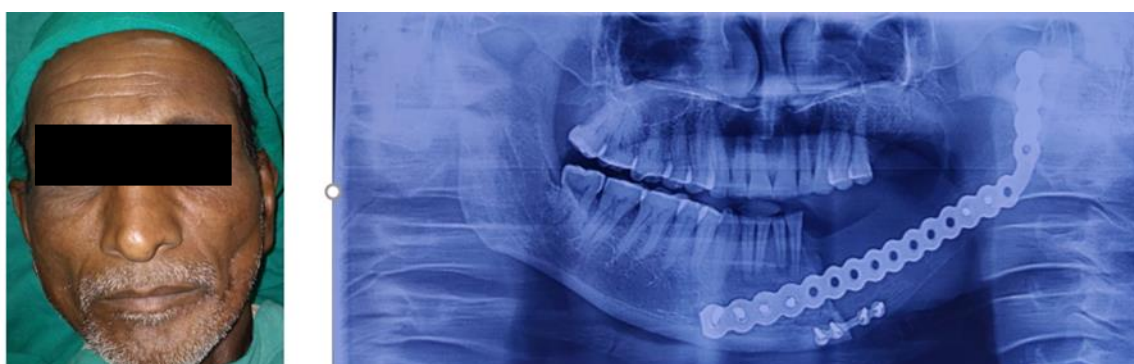

**Figure 1:** Pre-operative photographs





**Figure 2:** Segmental resection of mandible followed by reconstruction with rib graft



**Figure 3:** 1 year follow up photograph and OPG

### 3. Discussion

The most prevalent epithelial odontogenic tumor is ameloblastoma. It typically affects people between the ages of 20 and 40 (7). In order to prevent its recurrence, extensive surgical excision had been recommended for its management. If cortical perforation had occurred, the overlying periosteum and more than one centimeter of the normal margin of the mandible must be removed. Curette, cryotherapy, and enucleation, for example, have been associated with recurrence rates of 75–90 percent (9). According to Chana (10) and Disa, free tissue transfer is the best choice for reconstruction following the excision in terms of form, appearance, and function. However, when expertise in microvasculature is lacking; The best choice is a bone graft without vascularization.

The most common free flaps for the reconstruction of the mandible are the femur & iliac crest. To get the

perfect curvature of the mandible, osteotomy procedure is required for straight femur & iliac bone, which will lengthen the procedure and also fibula has less height compared to the mandible so this can be considered as the disadvantages of the fibula graft. Advantages of fibula flaps include faster flap harvest with less blood loss, adequate pedicle length, and sufficient length of fibular bone segment for any length of mandibular defect.(12) The fibular flap was more acceptable for the anterior mandibular defect because of its straight shape (13).

We believe that the best donor site for the reconstruction of mandible is the iliac crest due to its natural contour. Also an iliac crest has more than sufficient width & height for mandible reconstruction and has better osseointegration & adequate soft tissue for any type of reconstruction either composite or compound (14). Compared to the other free flaps, it has a good aesthetic appearance at the donor site. The

# Journal of Coastal Life Medicine

disadvantages of free iliac graft are: presence of excess fatty tissue in heavy patients, risk of hernia and the difficulty of dissection in comparison to the fibular flap (15). Anterior iliac crest graft has very good aesthetic and functional results after mandibular resection in ameloblastoma cases according to Anil Managutti (16) and Viral Patel (17).

Rib grafts are a good source of cortico-cancellous membranous bone. Fifth or sixth rib is harvested, for mandibular, maxillary and cranial reconstruction. The complications that can occur are pneumothorax, infection pleural tear and graft exposure (18).

In Ahmad, al. study of the fifty patients where mandible body reconstruction done with non-vascularized split rib graft after careful resection of Ameloblastoma, recurrences were not observed, despite the large tumor in their patient population. The symmetry, function, aesthetic appearance and shape of 90% of patients are good to excellent. Complications, such as one patient's intraoperative pleural puncture were repaired, and the infection was treated conservatively with antibiotics in accordance with the pus culture report (19).

The disadvantages and advantages of both flaps can be taken into consideration when selecting a flap. In addition to patient-dependent factors like age, gender, and obesity, the type of flap is selected based on the location and size of the mandibular defect.

## 4. Conclusion

After ameloblastoma resection, mandibular reconstruction can be done in a variety of ways, but rib grafting is best for larger defects. This is simple, takes less time, and produces outstanding results in facial symmetry, shape, function, and appearance.

## References

- [1] Torres-Lagares D, Infante-Cossío P, Hernández-Guisado JM, Gutiérrez-Pérez JL. Mandibular ameloblastoma. A review of the literature and presentation of six cases. *Med Oral Patol Oral Cir Bucal*. 2005; 10:231-8.
- [2] Adebisi KE, Ugboko VI, Omoniyi-Esan GO, Ndukwe KC, Oginni FO. Clinicopathological analysis of histological variants of ameloblastoma in a suburban Nigerian population. *Head Face Med*. 2006; 2:42.
- [3] Tozaki M, Hayashi K, Fukuda K. Dynamic multislice helical CT of maxillomandibular lesions: distinction of ameloblastomas from other cystic lesions. *Radiat Med*. 2001; 19:225-30.
- [4] Ogunsalu C, Daisley H, Henry K, Bedayse S, White K, Jagdeo B, et al. A new radiological classification for ameloblastoma based on analysis of 19 cases. *West Indian Med J*. 2006; 55:434-9.
- [5] Nakamura N, Mitsuyasu T, Higuchi Y, Sandra F, Ohishi M. Growth characteristics of ameloblastoma involving the inferior alveolar nerve: a clinical and histopathologic study. *Oral Surg Oral Med Oral Pathol Oral Radiol Endod*. 2001;91:557-62.
- [6] Gümgüm S, Hoğören B. Clinical and radiologic behaviour of ameloblastoma in 4 cases. *J Can Dent Assoc*. 2005;71:48
- [7] Williams TP (1993) Management of ameloblastoma: A changing perspective. *J Oral Maxillofac Surg* 51:1064
- [8] Olaitan AA, Adeola DS, Adekeye EO (1993) Ameloblastoma: clinical features and management of 315 cases from Kaduna, Nigeria. *J Craniomaxillofac Surg* 21:351-355
- [9] Gardner DG (1994). Controversies in the nomenclature, diagnosis and treatment of ameloblastoma. In: Worthington P, Evans JR (eds) *Controversies in Oral & Maxillofacial Surgery*. Saunders, Philadelphia, p 301
- [10] Chana JS, Chang YM, Wei FC, Shen YF, Chan CP, Lin HN, Tsai CY, Jeng SF (2004) Segmental mandibulectomy and immediate free fibula osteoseptocutaneous flap reconstruction with endosteal implants: an ideal treatment method for mandibular ameloblastoma. *Plast Reconstr Surg* 113(1):80-87
- [11] Disa JJ, Cordeiro PG (2000) Mandible reconstruction with microvascular surgery. *Semin Surg Oncol*. 19(3):226-234
- [12] Wei FC, Seah CS, Tsai YC, et al: Fibula osteoseptocutaneous flap for reconstruction of composite mandibular defects. *Plast Reconstr Surg* 93:294, 1994
- [13] Wei FC, Santamaria E, Chang YM, et al: Mandibular reconstruction with fibular osteoseptocutaneous free flap and simultaneous placement of osseointegrated dental implants. *J Craniofac Surg* 8:512, 1997

# Journal of Coastal Life Medicine

- [14] Daniel RK: Mandibular reconstruction with vascularized iliac crest: A 10-year experience (Discussion). *PlastRecontrSurg* 82:802, 1988
- [15] Boyd JB, Rosen I, Rotstein L, et al: The iliac crest and the radial forearm flap in vascularized oromandibular reconstruction. *Am J Surg* 159:301, 1990
- [16] Managutti A, Menat S, Shah D, Katwala H, Managutti S. *Scholars Journal of Medical Case Reports* ISSN 2347-6559 (Online).
- [17] Patel V, Managutti A, Menat S, Managutti S, Patel J. Management of Large Mandibular Ameloblastoma Crossing Midline: Reconstructed by Bilateral Iliac Crest Graft: A Rare Entity. *IJSS Case Reports & Reviews*. 2015 Apr;1(11):58-62.
- [18] Bonanthaya K, Panneerselvam E, Manuel S, Kumar VV, Rai A, editors. *Oral and Maxillofacial Surgery for the Clinician*. Springer Singapore; 2021.
- [19] Ahmad I, Choudhary R. Wide surgical excision with split rib graft reconstruction of mandible for ameloblastoma; our 10 year experience. *Indian Journal of Otolaryngology and Head & Neck Surgery*. 2013 Jan;65:40-3.